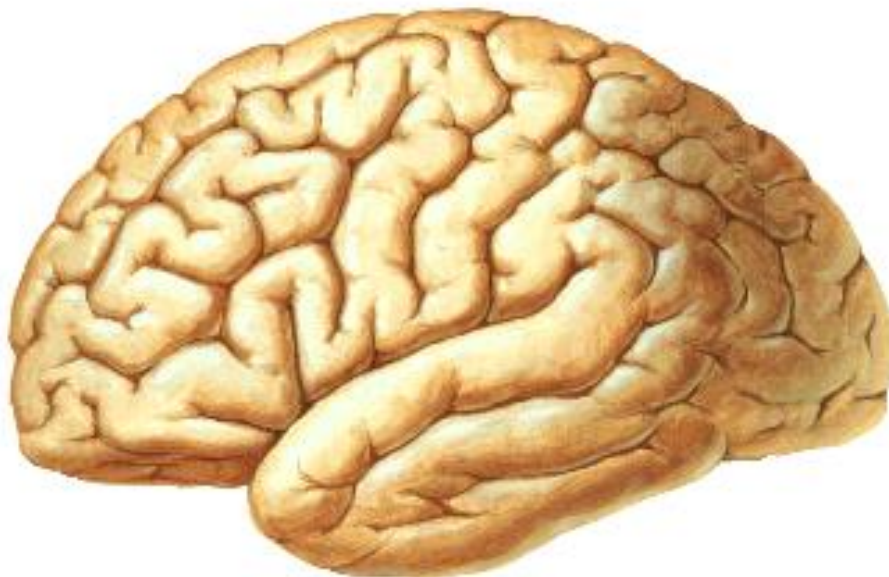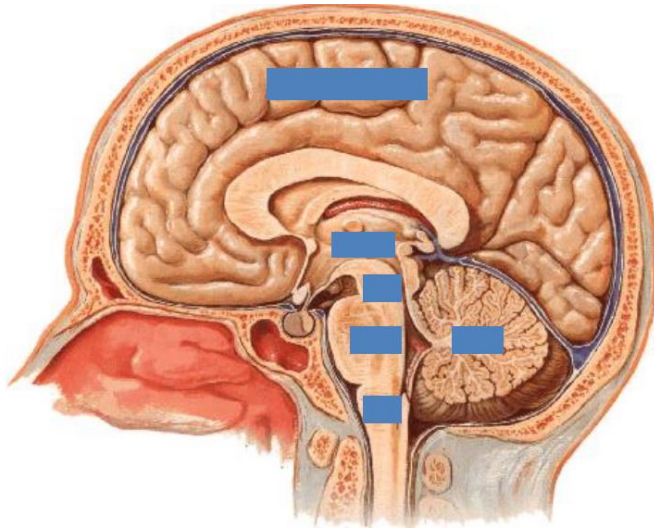


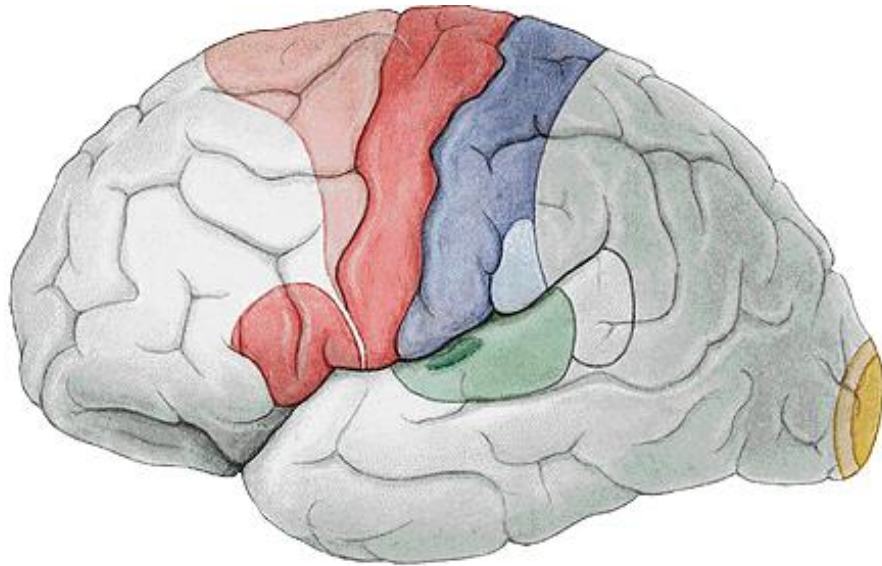
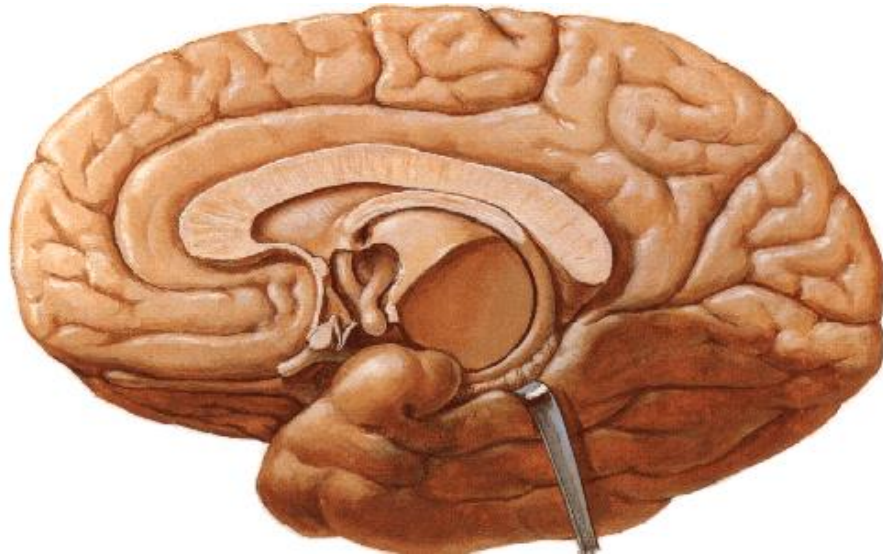
ESTUDO DIRIGIDO A1 – SOMENTE FIGURAS

CURSO FONOAUDIOLOGIA

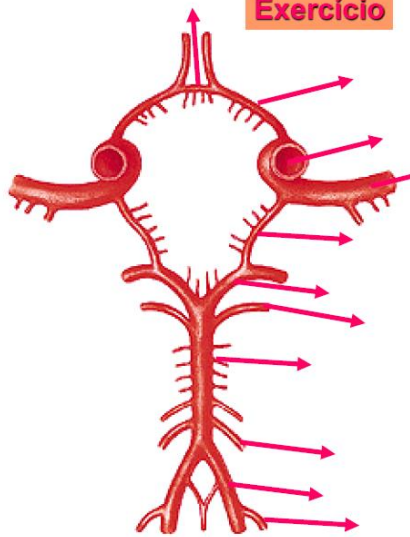
DISCIPLINA NEUROLOGIA CLÍNICA

Complete a figura:

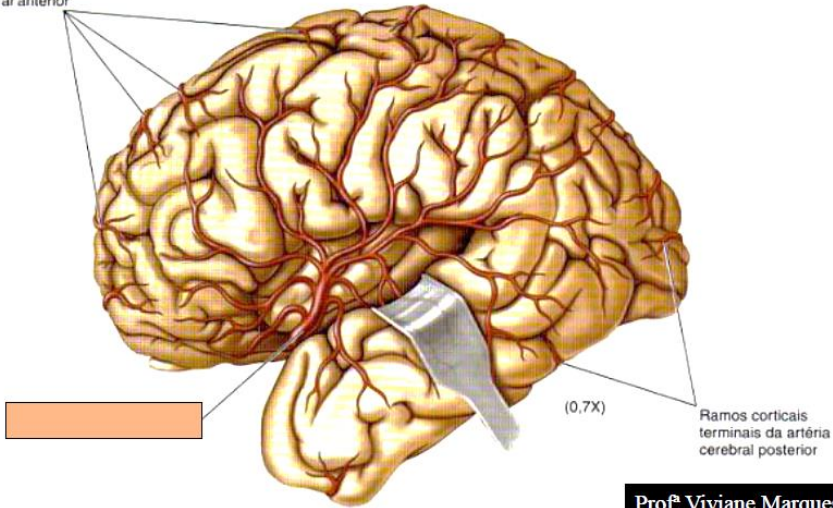




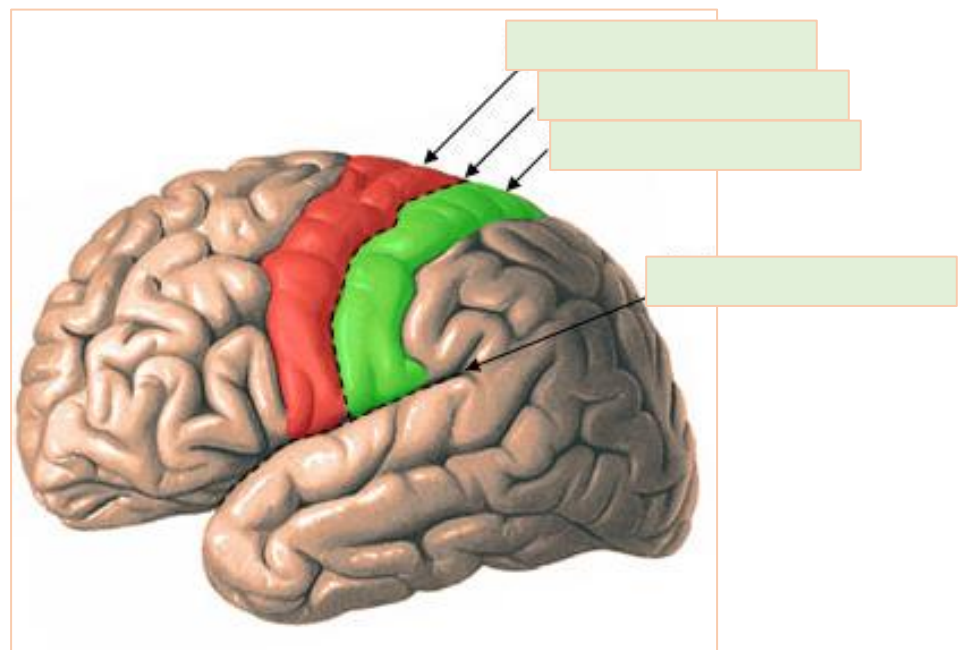
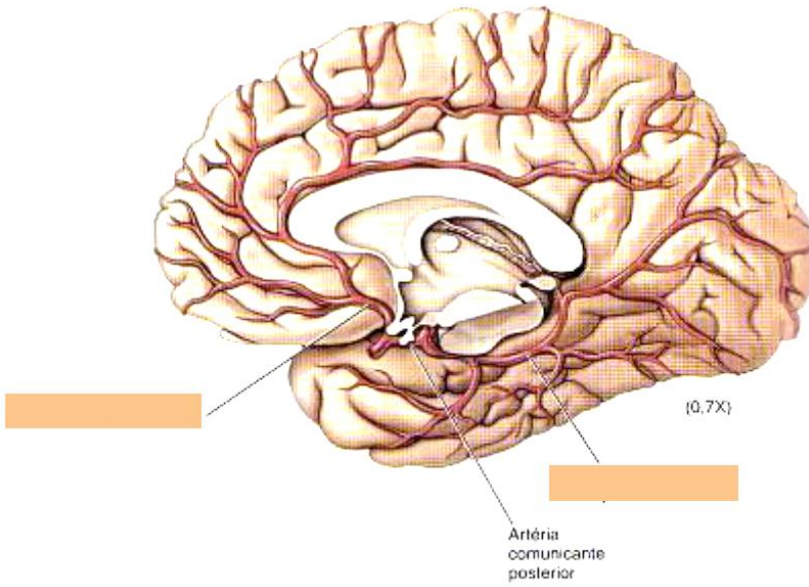
Exercício



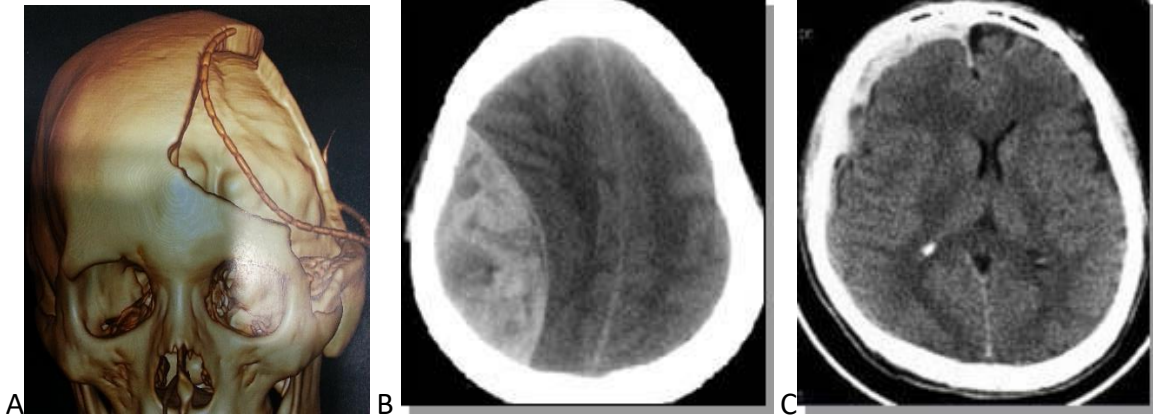
Ramos corticais terminais da artéria cerebral anterior



Prof Viviane Marques







13. Identifique as estruturas abaixo:

